
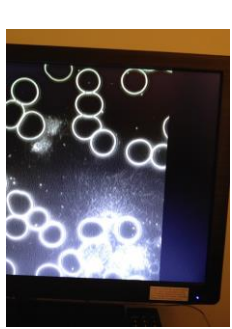





Pretest Live Blood Analysis Sun 1st Feb 2015 10:30 am

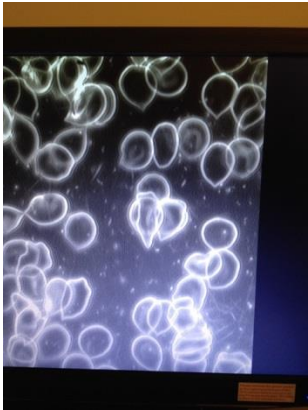
Notes: Clinic Closed. Everything off. All phones on airplane mode ON + location services OFF. Wifi OFF. No cordless phones. Nearest Tower 700m away.

Pretest Slides (photos of haemaview screen)			
			
Haemolysis (blinking out of red blood cells). Some red blood cells larger than others, fibrinoids Oxidative stress Liver toxicity	Some aggregation Oxidative stress	Some deformed red blood cells Oxidative stress	Signs of leaky gut
	<p>Overall diagnosis</p> <p>Red Blood Cells</p> <ul style="list-style-type: none"> • Signs of Leaky gut and Liver toxicity • Folate and mineral deficiencies <p>White Blood Cells</p> <ul style="list-style-type: none"> • Immune system: Active 		
Nice healthy white blood cell (sparkling) Immune system active			

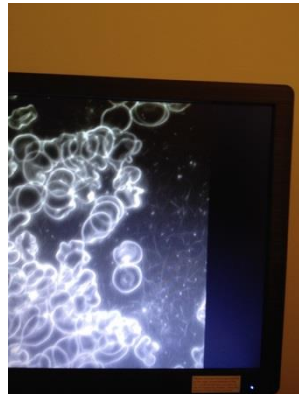
Exposure to EMR

- ½ hr of iphone 4S on, ipad 2 on
- Actively swiped on ipad for 5 minutes; practitioner swiped on iphone for 5 minutes
- EMR readings 200-1300 mV/m (Tenmars 3-axis field strength meter TM-196)
- Magnetic Field from Haemaview Equipment 1.2MG
- The did another test (see below)

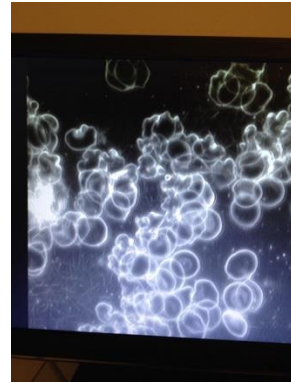
Post-test Slides (photos of haemaview screen)



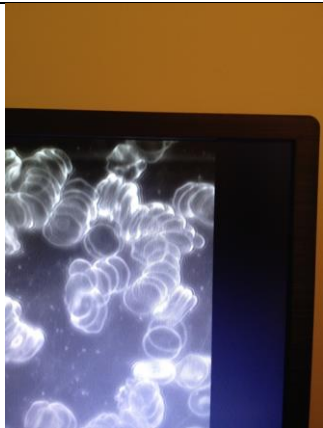
Haemolysis (blinking out of red blood cells). Some red blood cells larger than others, many deformations
Much Oxidative stress



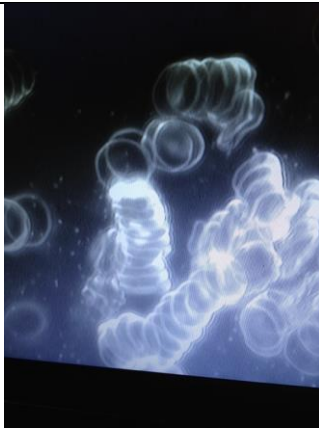
Much aggregation
Much Oxidative stress



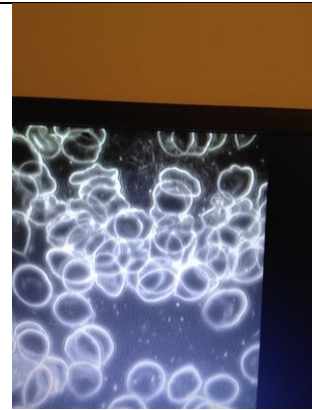Highly mutated RB cells
Heinz body
Oxidative stress



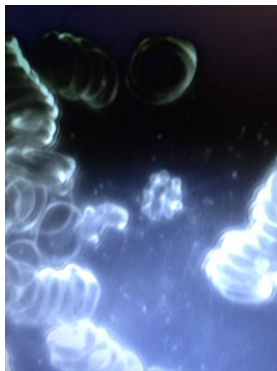
aggregation Roleaux
Much Oxidative stress



Much roleaux
Much Oxidative stress



Much aggregation
deformation
Much Oxidative stress



Pratitioner searchd and serched all slides. Could only find 1 white blood cell (1 lymphocyte)

Overall diagnosis

Red Blood Cells

- Highly damaged
- Showing extreme oxidative stress

White Blood Cells

- Immune system: Nuked

